

Effect of Obestatin on Hepatic Injury Induced by Renal Ischemia/Reperfusion in Rat

Aisha A. Muhammed^{1*}, Bouzeed S. Boukhazeem², Khlid G. Alqathafy³, Awad M. Alhasnony⁴, Ahmed G. Elsayed⁵ and Elsayed A. Emar⁶

¹Department of Physiology, Faculty of Medicine, Omar Al-Mukhtar University, Libya

²Department of Biochemistry, Faculty of Nursing, Tobruk University, Libya

³Department of Biochemistry, Faculty of Medicine, Benghazi University, Libya

⁴Department of Biochemistry, Faculty of Medicine, Tobruk University, Libya

⁵Department of Pathology, Tobruk Medical Center, Libya

⁶Department of Physiology, Faculty of Medicine, Tanta University, Egypt

Abstract

Background and Aims: Oxygen free radicals and cytokines are considered to be important components involved in the pathophysiological tissue alterations observed during Ischemia/Reperfusion (I/R). Based on the anti-oxidant and anti-inflammatory effects of Obestatin (OB), we investigated the putative protective role of OB against I/R-induced oxidative remote organ injury. **Materials and Methods:** Male albino rats were subjected to either sham operation or bilateral renal artery clamping for 45 min and reperfusion for 24 h to induce I/R damage. Obestatin was administered intraperitoneally twice a day at a dose of 8 nmol/kg. At the end of the experimental procedure, the rats were decapitated and hepatic tissue were removed for biochemical analyses of: Malondialdehyde (MDA), an end product of lipid peroxidation; the activity of antioxidant enzymes Superoxide Dismutase (SOD) and Catalase (CAT); the Myeloperoxidase (MPO) activity, as an indirect index of neutrophil infiltration and the level of pro-inflammatory cytokines (TNF- α and IL-1 β). The serum Aspartate Aminotransferase (AST), Alanine Aminotransferase (ALT) and Lactate Dehydrogenase (LDH) levels were measured to assess liver function and tissue damage, respectively. Pathological histology was also performed. **Results:** The results revealed the occurrence of I/R- induced oxidative organ damage, as confirmed histologically and evidenced by an increase in the MDA level and MPO activity, and a decrease in activity of SOD and CAT. Furthermore, serum AST, ALT, LDH levels, and tissue cytokines were elevated in the renal I/R group as compared to the sham operated control group. On the other hand, obestatin treatment succeeded to modulate these observed abnormalities resulting from I/R as indicated by the reduction of MDA and the pronounced improvement of the investigated biochemical and antioxidant parameters. **Conclusion:** Since obestatin administration reversed these oxidant responses, it seems likely that obestatin has a protective effect against oxidative organ damage induced by I/R.

Keywords: Obestatin (OB), Ischemia/Reperfusion (I/R), Oxidative Remote Organ Injury

1. Introduction

Acute Kidney Injury (AKI) is a common complication during major surgeries and is associated with increased risk of chronic kidney disease and mortality¹. However,

the morbidity and mortality from AKI is very high and remains virtually unchanged for the past 50 years in part due to a high incidence of extra-renal complications^{1,2}. In particular, hepatic dysfunction is very frequent in patients suffering from AKI. Furthermore, development

of liver injury in patients with AKI frequently leads to other extra-renal complications including intestinal barrier disruption, respiratory failure and the systemic inflammatory response syndrome with the eventual development of sepsis and a multi-organ failure³⁻⁵. These extra-renal systemic complications secondary to AKI are the leading causes of mortality in the intensive care unit⁶. Indeed, clinical studies show that patients with isolated AKI have significantly better prognosis than patients with AKI plus extra-renal organ dysfunction⁷.

Ischemia reperfusion is a frequently encountered phenomenon in organisms. Prolonged ischemia followed then by reperfusion results in severe oxidative injury in tissues and organs⁸. Renal Ischemia Reperfusion (RIR) is a common cause of AKI⁸. RIR injury occurs in many clinical situations, such as transplantation, partial nephrectomy, sepsis, hydronephrosis, or elective urological operations¹⁰. Mortality during AKI is largely due to extra renal manifestations^{11,12}.

Liver injury is one of the distant organ damage induced by RIR. Acute renal failure associated with liver disease is a commonly encountered clinical problem of varied etiology¹³. It is believed that IR injury induces inflammatory response, that elicits tissue damage in a number of organs in which reactive oxygen and nitrogen species play a key role in the pathophysiology of RIR injury^{13,14}. It demonstrated that RIR injury may cause liver oxidative stress and increase lipid peroxidation in liver tissue¹⁵. The liver tissue of rat decreases antioxidant enzyme activities after RIR is well reported¹⁶.

Obestatin is an interesting but controversial gut hormone¹⁷. Obestatin is a circulating 23-amino-acid peptide, encoded by the same gene as ghrelin¹⁸. It is predominantly produced in the stomach, and exhibits a wide range of peripheral effects including inhibition of food intake, body weight gain, gastric emptying and regulation of jejunal motility^{18,19}. Interestingly, several previous studies have demonstrated the protective and regenerative effects of the preproghrelin gene-derived peptides, including obestatin and ghrelin in the gastrointestinal tract, kidney and heart²⁰⁻²². Likewise, a positive effect of obestatin has also been observed in the pancreas, where the peptide exhibited protective action in cerulein-induced pancreatitis²³.

The anti-oxidant and anti-inflammatory effects of obestatin were previously demonstrated²⁴⁻²⁶. As the main mechanism of RIR injury is via inflammation and oxidative stress, this study was designed to evaluate the possible protective effect of obestatin on oxidative liver injury (distant organ) induced by RIR in rats.

2. Materials and Methods

2.1 Experimental Animals

All animal procedures were approved by the ethical committee of Faculty of Medicine, Tanta University. Thirty male Albino rats in the range of 230–280 g body weight were used in this study. All subjects were kept in an animal room of Physiology Department of Faculty of Medicine, Tanta University, in a controlled temperature and 12:12 h light/dark cycle with free access to food and water.

The animals were divided into 3 groups of 10 animals each.

Group-1: the sham group (sham operated, no I/R).

Group-2: the vehicle group (renal I/R rats treated with normal saline).

Group-3: the ghrelin group (renal I/R rats treated with obestatin).

2.2 Surgical Procedure

Rats were placed on a warming pad and anesthetized with pentobarbital sodium (60 mg/kg, intraperitoneally). Body temperature was maintained at 37 ± 1 °C. A tracheotomy was performed to facilitate free breathing. The tail vein was cannulated for infusion of 0.9% NaCl solution. A midline laparotomy was performed and the renal arteries were carefully separated from around the tissues.

In the I/R groups, renal arteries were occluded by a non-traumatic micro-vascular clips for 45 min, followed by 24 h reperfusion. Occlusion was approved visually by color change of the kidney to a paler shade and reperfusion by blushing. Sham operated animals underwent identical surgical treatment, including isolation of both renal arteries. However, artery occlusion was not performed. At the end of the experimental procedure, the animals were decapitated and trunk blood samples were collected to determine serum aspartate aminotransferase (AST), alanine aminotransferase (ALT) and lactate dehydrogenase (LDH) levels as indicators of liver function and damage, respectively. Liver samples were taken and stored at -70°C for the measurement of Pro-inflammatory cytokines (TNF- α and IL-1 β) and malondialdehyde (MDA) levels, superoxide dismutase (SOD), catalase (CAT) and myeloperoxidase (MPO) activities were measured. Additional liver samples were fixed with 10% formaldehyde for histopathological evaluation.

2.3 Administration of Obestatin

Rat obestatin was obtained from Yanaihara Institute (Shizuoka, Japan). Treatment with obestatin was started 24 hours after the beginning of renal reperfusion. Obestatin was administered intraperitoneally twice a day at a dose of 8nmol/kg. This dose of obestatin was determined from a previous model of injury²⁷. An equal volume of the saline was injected into the vehicle rats. The sham group of animals only underwent laparotomy.

2.4 Estimation of Liver Function and Damage

Serum AST, ALT and LDH activities were determined to assess the liver damage by using AST, ALT and LDH (Roche Diagnostic, Mannheim, Germany) commercial kits in a Roche- Hitachi Modular Auto analyzer (Roche Diagnostic).

2.5 Estimation of Cytokine Concentrations

TNF- α and IL-1 β levels were determined by using a commercially available rat ELISA kit (MedSystems Diagnostics GmbH, Vienna, Austria) and the results were expressed as pictograms per milligram protein.

2.6 Estimation of Lipid Peroxidation and Antioxidant Enzymes

Malondialdehyde (MDA) was determined in liver homogenates using commercial kits (LPO-585) from Bioxytec (Bioxytec, Portland, USA). Superoxide dismutase (SOD) and catalase (CAT) activities were measured according to Sun et al.²⁸ and Luck²⁹ respectively.

2.7 Determination of Myeloperoxidase Activity

Tissue samples (0.2–0.3 g) were homogenized in 10 vol of ice-cold potassium phosphate buffer (50 mmol/L K₂HPO₄, pH 6.0) containing hexadecyltrimethylammonium bromide (HETAB; 0.5%, w/v). The homogenate was centrifuged at 30,000 g for 10 min at 4 °C, and the supernatant was discarded. The pellet was then rehomogenized with an equivalent volume of 50 mmol/L K₂HPO₄ containing 0.5% (w/v) HETAB and 10 mmol/L ethylenediaminetetraacetic acid (EDTA, Sigma). MPO activity was assessed by measuring the H₂O₂-dependent oxidation of o-dianizidine.2HCl. One unit of

enzyme activity was defined as the amount of the MPO present per gram of tissue weight that caused a change in absorbance of 1.0/min at 460 nm and 37 °C³⁰.

2.8 Histopathological Evaluation

For light microscopic examinations, liver samples were fixed in 10% neutral buffered formalin solution. The tissues were embedded in paraffin. The paraffin blocks were cut in 5 μ m thick. The sections were stained with Hematoxylin-Eosin (H&E). All tissue sections were examined microscopically for the characterization of histopathological changes by an experienced histologist in blind fashion.

2.9 Statistical Analysis

All the values are expressed as mean \pm SEM. Statistical significance between more than two groups were tested using one-way ANOVA followed by the Bonferroni multiple comparisons test using computer based fitting program (Prism, Graphpad 5). Differences were considered to be statistically significant when P < 0.05.

Table 1. Changes in serum alanin amimotransaminase (ALT), Aspartate Amimotransaminase (AST) and lactate dehydrogenase (LDH) levels in the Sham, Vehicle (RIR +saline) and Obestatin (RIR+ OB) Groups. Each group consists of ten rats.

Groups	Measured parameters		
	ALT (U/L)	ALT (U/L)	LDH (U/L)
Sham group	47 \pm 4.7	82 \pm 6.2	811 \pm 67 ⁺
Vehicle group (RIR +saline)	255 \pm 9.7*	218 \pm 14.5*	1332 \pm 139*
Obestatin group (RIR+OB)	121 \pm 5.3 ⁺	130 \pm 6.5 ⁺	533 \pm 92 ⁺

Data are expressed as mean \pm S.E.M.

*P < 0.05 compared with sham group.

[†]P < 0.05 compared with vehicle group.

3. Results

3.1 Effect of Obestatin on Liver Function and Damage

Renal IR-induced liver injury caused significant increases in the ALT and AST levels indicating impairment of liver functions. Similarly, LDH activity, as an index

of generalized tissue damage was also found to be increased compared with the control. When obestatin was administered 24 hours after the beginning of renal reperfusion, these elevations were significantly depressed ($P < 0.05$) (Table 1).

3.2 Effect of Obestatin on Lipid Peroxidation and Antioxidant Enzymes

The liver tissue MDA content in the sham operated control group was elevated by renal I/R injury ($P < 0.05$); however, obestatin treatment significantly decreased the renal I/R-induced elevation in liver MDA level ($P < 0.05$; Table 2). In accordance with this, renal I/R caused a significant decrease in the activities of hepatic antioxidant enzymes (SOD) and (CAT) ($P < 0.05$) compared with sham operated control group, while in the obestatin-treated renal I/R group, activities of hepatic anti-oxidant enzymes (SOD) and (CAT) was found to be preserved significantly ($P < 0.05$), not significantly different from that of the control group (Table 2).

Table 2. Changes in liver MDA level and SOD and CAT activities in the Sham, Vehicle (RIR + saline) and Obestatin (RIR+ OB) Groups. Each group consists of ten rats.

Groups	Measured parameters		
	MDA (nmol/mg-protein)	SOD (U/mg-protein)	CAT (U/mg-protein)
Sham group	6.15 ± 1.14*	82.6 ± 7.8	17.93 ± 2.08
Vehicle group (RIR +saline)	6.15 ± 1.14*	49.7 ± 16.8*	12.34 ± 1.43*
Obestatin group (RIR+OB)	3.77 ± 1.12 [†]	73.8 ± 12.2 [†]	16.39 ± 1.25 [†]

Data are expressed as mean ± S.E.M.

* $P < 0.05$ compared with sham group.

[†] $P < 0.05$ compared with the vehicle group.

3.3 Effect of Obestatin on Cytokine Concentrations

Pro-inflammatory cytokines (TNF- α and IL-1 β) levels were significantly higher in the liver tissue of the vehicle saline-treated I/R group ($P < 0.05$) than that of the sham- operated control group (Table 3). On the other hand, obestatin treatment in the I/R group decreased the elevations in levels of pro-inflammatory cytokines (TNF- α and IL-1 β) significantly ($P < 0.05$).

Table 3. Changes in hepatic TNF- α , and IL-1 β Levels in the Sham, Vehicle (RIR + saline) and Obestatin (RIR + OB) Groups. Each group consists of ten rats

Groups	Measured parameters	
	TNF- α (pg/mg)	IL-1 β (pg/mg)
Sham group	1.2 ± 0.3	11.3 ± 1.3
Vehicle group (RIR +saline)	7.4 ± 0.8*	18.3 ± 1.2*
Obestatin group (RIR+OB)	4.2 ± 0.6 [†]	9.4 ± 0.6 [†]

Data are expressed as mean ± S.E.M.

* $P < 0.05$ compared with the Sham group.

[†] $P < 0.05$ compared with the Vehicle group.

3.4 Effect of Obestatin on Myeloperoxidase Activity

Myeloperoxidase activity, which is accepted as an indicator of neutrophil infiltration, was significantly higher in the liver tissue of the vehicle saline-treated I/R group ($P < 0.05$) than that of the sham - operated control group (Table 4). On the other hand, obestatin treatment in I/R group significantly decreased liver tissue MPO level ($P < 0.05$).

3.5 Histopathological Study

In the vehicle group (RIR + saline), areas of hepatocyte necrosis in the liver parenchyma, lymphocytic infiltration, expansion of sinusoids and scattered congestion were detected. Hepatocyte damage was not observed in the liver parenchyma of the obestatin group (RIR + OB) except for scattered necrotic hepatocytes. Expansion of blood sinusoids was less compared to the vehicle group (RIR + saline). These observations are illustrated in (Figure 1).

Table 4. Changes in myeloperoxidase activity in the Sham, Vehicle (RIR + saline), and Obestatin (RIR + OB) Groups. Each group consists of ten rats

Groups	Measured parameters
	Myeloperoxidase (U/g)
Sham group	10.8 ± 0.5
Vehicle group (RIR +saline)	19.1 ± 1.2*
Obestatin group (RIR+OB)	14.3 ± 1.1 [†]

Data are expressed as mean ± S.E.M.

* $P < 0.05$ compared with the sham group.

[†] $p < 0.05$ compared with the Vehicle group.

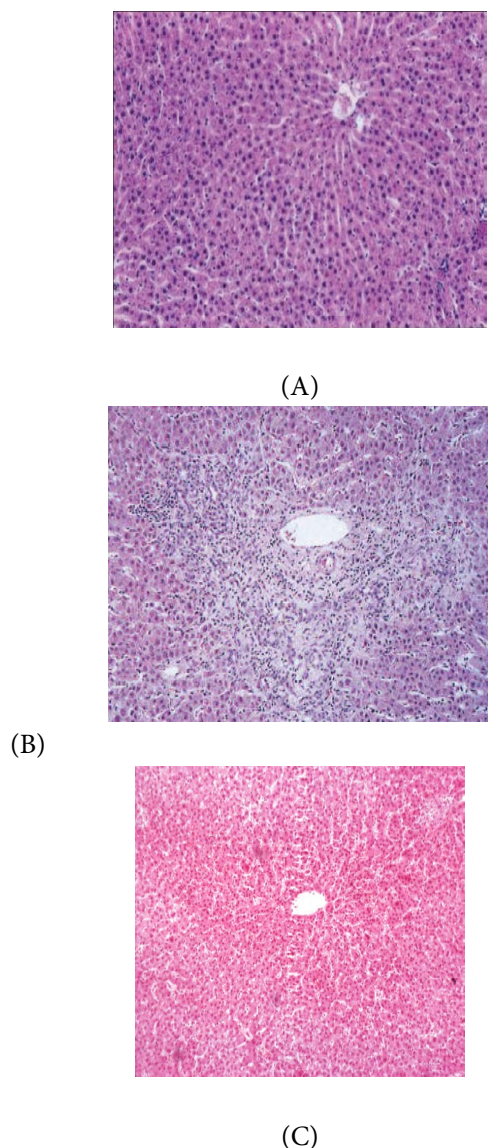


Figure 1. The effect of obestatin treatment in the liver of rats (Hematoxylin and Eosin stain). (A) Sham group, (B) Vehicle group (RIR + saline), (C) Obestatin group (RIR + OB) [H&E X100].

4. Discussion

The present study demonstrated that Obestatin (OB) administration in RIR-induced hepatic injury improved the liver functions and decreased the elevations in serum LDH activity and pro-inflammatory cytokine levels. Furthermore, increased myeloperoxidase activity and hepatic lipid peroxidation level and decreased activity of antioxidant enzymes that were observed as the consequences of oxidative injury were also reversed by obestatin treatment. Histopathologic findings also

supported the anti-inflammatory effects of obestatin in RIR-induced hepatic damage.

Ischemia/reperfusion injury is a complex process involving numerous intracellular signaling pathways, mediators, cells, and pathophysiological disturbances; its prevention during surgery is of utmost importance³¹. It has been suggested that I/R triggers a series of reactions mainly in the organ which is clamped and reperfused, and these reactions elicit a systemic inflammatory response by the release of cytokines and inflammatory mediators (tumor necrosis factor- α , interleukin-6, nitric oxide, etc.) which cause the generation of free radicals^{32,33}. Inflammatory mediators released as a consequence of reperfusion activate endothelial cells and circulating neutrophils in remote organs that are not exposed to the initial ischemic insult. This distant response to I/R can result in leukocyte-dependent microvascular injury that is characteristic of multiple organ dysfunction syndrome^{34,35}. Park et al demonstrated that acute kidney ischemia causes small intestinal generation of IL-17A and subsequent intestinal injury (villous endothelial apoptosis, epithelial necrosis, increased pro-inflammatory cell translocation and cytokine flux to the liver). These events cause hepatic injury (inflammation, apoptosis and necrosis) with increased generation and release of TNF- α and IL-6 systemically causing further multi-organ injury and systemic inflammation³⁶. As a result, in this study, although the liver tissue specimen was not exposed to ischemia directly, we aimed to investigate whether I/R caused remote organ injury as a result of a systemic effect.

Several studies have demonstrated that ischemia and reperfusion of the tissue to be associated with lipid peroxidation, which is an autocatalytic mechanism leading to oxidative destruction of the cellular membranes, and their destruction can lead to the production of toxic, reactive metabolites and cell death³⁷. Lipid peroxidation, as a free radical-generating system, has been suggested to be closely related to I/R-induced tissue damage, and MDA is a good indicator of the rate of lipid peroxidation. In the present study, the levels of MDA significantly increased due to I/R. This observation correlates with previous studies, in which the elevated levels of lipid peroxidation products increased from 40% to 100% above the basal values^{13,38}.

Our results show that obestatin caused a significant inhibition in MDA production, thus indicating a reduction in lipid peroxidation and cellular injury. This result agrees

with previous findings showing that obestatin induced reduction of the increased level of MDA in a rat model of colitis^{24,39}. Similarly, Koyuncuoğlu *et al.*³⁹ demonstrated that obestatin reduced seizure-induced lipid peroxidation and oxygen-derived radicals in brain. Likewise, Ersahin *et al.*⁴⁰ showed that obestatin administration significantly decreased MDA level in the subarachnoid haemorrhage-induced oxidative injury in rats.

Reactive Oxygen Species (ROS), such as superoxide anion, hydroxyl radical, and hydrogen peroxide, have a causal relationship with oxidative stress. Antioxidant enzymes such as SOD and CAT represent protective response against oxidative tissue-damage. SOD converted superoxide anion into H₂O₂. Catalase metabolize H₂O₂ to water. Maintaining the balance between ROS and antioxidant enzymes is therefore crucial, and could serve as a major mechanism in preventing damage by oxidative stress. In the present study, we observed a decrease in the activities of SOD and CAT in liver induced by RIR. This decrease may be attributed to oxidative inactivation of enzyme protein by lipid peroxyl radicals and excess ROS generation. Treatment with obestatin showed an improved effect on the activities of antioxidant enzymes examined as compared to vehicle group. Our results confirm previous data concerning the antioxidative properties of obestatin in other tissues^{24,40}.

The pro-inflammatory cytokines, TNF- α and IL-1 β , are known to play pivotal roles in the pathogenetic mechanisms of remote organ injury⁴². Following experimental AKI, hepatic TNF- α , IL-6 and IL-17A are increased^{36,43}. Knockout mice for TNF- α , IL-17A, and IL-6 displayed reduced hepatic injury after renal ischemia, as did wild-type mice treated with antibodies to the cytokines³⁶. Ceranowicz *et al.*²³ reported that administration of obestatin reduces the severity of cerulein-induced acute pancreatitis, by significantly raising the pancreatic blood flow and reducing the proinflammatory IL-1 β release. Similarly, El-malkey and Abdel moety revealed that administration of obestatin maintains a balance in oxidant-antioxidant status through the increase in endogenous antioxidants and the decrease in pro-inflammatory mediators in rat model of Chron's disease²⁴. In accordance with these observations, the findings of the current study show that obestatin treatment ameliorated RIR-induced oxidative hepatic injury by a mechanism that involves an inhibitory effect on the release of inflammatory cytokines.

Liver dysfunction and cell injury induced by neutrophils have been demonstrated in a number of experimental models, including ischemic reperfusion injury⁴⁴. Several methods have been used to define the role of neutrophils in the tissue injury. One of them is to measure the activity of neutrophil-specific enzyme, MPO, which is released as a response to various stimulatory substances⁴⁵. In the present study, increased hepatic MPO activity due to RIR indicates that liver injury involves the contribution of neutrophil infiltration. Since obestatin depressed the tissue MPO activity in concomitant with its anti-inflammatory effect, it appears that the mode of action of obestatin treatment in hepatic injury involves its inhibitory effect on tissue neutrophil infiltration that limits neutrophil-derived oxidative tissue damage.

In the present study following I/R injury, plasma ALT, AST, and LDH levels were increased indicating impairment of liver functions and generalized tissue damage, respectively, while these increases were significantly reduced by obestatin treatment. Our findings were also confirmed by histological observation. Hepatocyte necrosis areas randomly disseminated in the liver parenchyma with disintegrated cell cordons, leucocyte infiltration, expansion of sinusoids and congestion were displayed after RIR. Treatment with ghrelin markedly reduced these histopathological changes.

In conclusion, since the administration of obestatin inhibited the release of the pro-inflammatory cytokines and the accumulation of neutrophils in the damaged hepatic tissue, these agents appear to play a cytoprotective role in the liver insulted by I/R. It seems likely that obestatin, with its efficiency as antioxidant and antiinflammatory, thus merits consideration as a potential therapeutic agent against I/R-induced oxidative remote organ damage.

5. References

1. Hobson C, Ozrazgat-Baslanti T, Kuxhausen A, Thottakkara P, Efron PA, Moore FA, et al. Cost and mortality associated with postoperative acute kidney injury. *Annals Surgery*. 2015; 261:1207–14.
2. Bove T, Calabro MG, Landoni G, Aletti G, Marino G et al. The incidence and risk of acute renal failure after cardiac surgery. *Journal of Cardiothoracic and Vascular Anesthesia*. 2004; 18:442–45.
3. Elapavaluru S, Kellum JA. Why do patients die of acute kidney injury? *Acta Clinica Belgica*. 2007; 326–31.

4. Paladino JD, Hotchkiss JR, Rabb H. Acute kidney injury and lung dysfunction: A paradigm for remote organ effects of kidney disease? *Microvascular Research*. 2009; 77:8–12.
5. Grigoryev DN, Liu M, Hassoun HT, Cheadle C, Barnes KC, Rabb H. The local and systemic inflammatory transcriptome after acute kidney injury. *Journals of the American Society of Nephrology*. 2008; 19:547–58.
6. Faubel S. Pulmonary complications after acute kidney injury. *Advances in Chronic Kidney Disease*. 2008; 15:284–96.
7. Bagshaw SM, Laupland KB, Doig CJ, Mortis Get al. Prognosis for long-term survival and renal recovery in critically ill patients with severe acute renal failure: A population-based study. *Critical Care*. 2005; 9:R700–9.
8. Tan DX, Manchester LC, Sainz RM, Mayo JC, León J, Reiter RJ. Physiological ischemia/reperfusion phenomena and their relation to endogenous melatonin production: A hypothesis. *Endocrine*. 2005 Jul; 27(2):149–58.
9. Liu M, Liang Y, Chigurupati S, Lathia JD, Pletnikov M, Sun Z et al. acute kidney injury leads to inflammation and functional changes in the brain. *Journals of the American Society of Nephrology*. 2008 Jul; 19(7):1360–70.
10. Kadkhodae M, Golab F, Zahmatkesh M, Ghaznavi R. Effects of different periods of renal ischemia on liver as a remote organ. *World Journal of Gastroenterology*. 2009 Mar 7; 15(9):1113–18.
11. Rabb H, Chamoun F, Hotchkiss J. Molecular mechanisms underlying combined kidney-lung dysfunction during acute renal failure. *Contributions to Nephrology*. 2001:41–52.
12. Kelly KJ. Acute renal failure: Much more than a kidney disease. *Seminars in Nephrology*. 2006; 26:105–113.
13. Serteser M, Koken T, Kahraman A, Yilmaz K, Akbulut G, Dilek ND. Changes in hepatic TNF- α levels, antioxidant status, and oxidation products after renal ischemia/reperfusion injury in mice. *Journal of Surgical Research*. 2002; 107:234–40.
14. Erdogan H, Fadillioğlu E, Yagmurca M, Uçar M, Irmak MK. Protein oxidation and lipid peroxidation after renal ischemia reperfusion injury: protective effects of erdosteine and Nacetylcysteine. *Urological Research*. 34; 2006:41–6.
15. Yildirim A, Gumus M, Dalga S, et al: Dehydroepiandrosterone improves hepatic antioxidant systems after renal ischemia-reperfusion injury in rabbits. *Annals of clinical and Laboratory Science*. 2003; 33:459–64.
16. Emre MH, Erdogan H, Fadillioğlu E. Effect of BQ-123 and nitric oxide inhibition on liver in rats after renal ischemia-reperfusion injury. *General Physiology and Biophysics*. 2006; 25:195–206.
17. Lacquaniti A, Donato V, Chirico V, Buemi A, Buemi M. Obestatin: An interesting but controversial gut hormone. *Annals of Nutrition and Metabolism*. 2011; 59:193–9.
18. Li JB, Asakawa A, Cheng K, Li Y, Chaolu H, Tsai M, Inui A. Biological effects of obestatin. *Endocrine*. 2011; 39(3):205–11.
19. Trovato L, Gallo D, Settanni F, Gesmundo I, Ghigo E, Granata R. Obestatin: Is it really doing something? *Frontiers of Hormone Research*. 2014; 42:175–85.
20. Sen LS, Karakoyun B, Yeşen C, Akkiprik M. et al: treatment with either obestatin or ghrelin attenuates mesenteric ischemia-reperfusion-induced oxidative injury of the ileum and the remote organ lung. *Peptides*. 2015; 71:8–19.
21. Koç M, Kumral ZN, Özkan D, Memi G, Kaçar Ö, Bilsel S et al. Obestatin improves ischemia/reperfusion-induced renal injury in rats via its antioxidant and anti-apoptotic effects: role of the nitric oxide. *Peptides*. 2014; 60:23–31.
22. Zhang Q, Dong X-W, Xia J-Y, Xu KY, Xu ZR. Obestatin plays beneficial role in cardiomyocyte injury induced by ischemia-reperfusion in vivo and in vitro. *Medical Science Monitor*. 2017; 23:2127–36.
23. Ceranowicz P, Warzecha Z, Dembinski A, Cieszkowski J et al. Pretreatment with obestatin inhibits the development of cerulein-induced pancreatitis. *Journal of Physiology and Pharmacology*. 2009; 60(3):95–101.
24. El-malkey N, Moety DA. Effect of obestatin on experimentally-induced Chron's Disease in Rats. *Medical Journal Cairo University*. 2017; 85(3).
25. Konarska K, Cieszkowski J, Warzecha Z, Ceranowicz P, Chmura A et al. Treatment with obestatin—a ghrelin gene-encoded peptide—reduces the severity of experimental colitis evoked by trinitrobenzene sulfonic acid. *International Journal of Molecular Sciences*. 2018; 19:1643.
26. Ibrahim R, Allam M, El-Gohary O et al. Protective effect of obestatin on indomethacin-induced acute gastric ulcer in rats: Role of VEGF and TNF- α . *Benha Medical Journal*. 2018 Sep–Dec; 35(3):369–77.
27. Bukowczan J, Warzecha Z, Ceranowicz P et al: Obestatin Accelerates the Recovery in the Course of Ischemia/Reperfusion-Induced Acute Pancreatitis in Rats. *PLoS One*. 2015 Jul 30;10(7).
28. Sun Y, Oberley LW, Li Y. A simple method for clinical assay of superoxide dismutase. *Clinical Chemistry*. 1988 Mar; 34(3):479–500.
29. Luck H. Catalase. In: Bergmeyer H, editor. *Methods of enzymatic analysis*. Academic Press, New York; 1965. p. 855–84.
30. Hillegas LM, Griswold DE, Brickson B, Albrightson-Winslow C: Assesment of myeloperoxidase activity in whole rat kidney. *Journal of Pharmacological Methods*. 1990; 24:285–95.
31. Sakon M, Ariyoshi H, Umeshita K, Monden M. Ischemia-reperfusion injury of the liver with special reference to calcium dependent mechanisms. *Surgery Today*. 2002; 32:1–12.

32. Rabb H, Daniels F, O'Donnell M, Haq M, Saba S, Keane W, et al. Pathophysiological role of T lymphocytes in renal ischemia-reperfusion injury in mice. *American Journal of Physiology: Renal Physiology*. 2000; 279:525–31.
33. Yassin MM, Harkin DW, Barros D'Sa AA, Halliday MI, Rowlands BJ. Lower limb ischemia-reperfusion injury triggers a systemic inflammatory response and multiple organ dysfunction. *World Journal of Surgery*. 2002; 26:115–21.
34. Carden DL, Granger DN: Pathophysiology of ischemia-reperfusion injury. *Journal of Pathology*. 2000; 190:255–66.
35. Khastar H, Kadkhodae M, Sadeghipour HR et al. Liver oxidative stress after renal ischemia-reperfusion injury is leukocyte dependent in inbred mice. *Iranian Journal of Basic Medical Sciences*. 2011 Nov–Dec; 14(6):534–9.
36. Park SW, Chen SW, Kim M et al: Cytokines induce small intestine and liver injury after renal ischemia or nephrectomy. *Laboratory Investigation*. 2011; 91:63–84.
37. Eschwege P, Paradis V, Conti M, Holstege A, Richet F, Deteve J, et al: In situ detection of lipid peroxidation by-products as markers of renal ischemia injuries in rat kidneys. *Journal of Urology*. 1999; 162:553–7.
38. Sumimoto K, Oku J, Dohi K, Kawasaki T. Lipid peroxidation in transplanted rat liver. *Transplantation Proceedings*. 1990; 22:2023–4.
39. Pamukcu O, Kumral ZN, Ercan F et al. Anti-inflammatory effect of obestatin and ghrelin in dextran sulfate sodium-induced colitis in rats. *Journal of Pediatric Gastroenterology and Nutrition*. 2013 Aug; 57(2):211–18.
40. Koyuncuoğlu T, Vızdıklar C, Üren D, Yılmaz H et al. Obestatin improves oxidative brain damage and memory dysfunction in rats induced with an epileptic seizure. *Peptides*. 2017 Apr; 90:37–47.
41. Ersahin M, Özsavci D, Sener A, Ozakpınar OB, Toklu HZ, Akakin D et al. Obestatin alleviates subarachnoid haemorrhage-induced oxidative injury in rats via its anti-apoptotic and antioxidant effects. *Brain Injury*. 2013; 27(10):1–9.
42. Halliwell B, Gutteridge JMC. Role of free radicals and catalytic metal ions in human disease: An overview. *Methods in Enzymology*. 1990; 186:59–85.
43. Aikawa N. Cytokine storm in the pathogenesis of multiple organ dysfunction syndrome associated with surgical insults. *Nippon Geka Gakkai Zasshi*. 1996 Sep; 97(9):771–7.
44. Golab F, Kadkhodae M, Zahmatkesh M et al. Ischemic and non-ischemic acute kidney injury cause hepatic damage. *Kidney International*. 2009; 75:783–92.
45. Jaeschke H, Hasegawa T. Role of neutrophils in acute inflammatory liver injury. *Liver International*. 2006; 26:912–9.
46. Kettle AJ, Winterbourn CC. Myeloperoxidase: A key regulator of neutrophil oxidant production. *Redox Report*. 1997; 3:3–15.