

Facial Medial Dermoid Cyst – A Case Report

Sajad Ahmad Salati*

Department of Surgery, Unaizah College of Medicine, Qassim University, KSA
Email: docsajad@gmail.com

Abstract

An anterior facial medial dermoid cyst at the frontonasal suture in a 7-year-old male child is presented along with the images of computed tomography (CT) study. The CT scan images show clear nasal bone indentation with no erosion. Dermoid cysts are a subtype of benign heterotopic lesions termed choristomas and contain cutaneous elements which include squamous epithelium and dermal appendages such as hair, sebaceous glands, and sweat glands. Of all the pediatric head and neck dermoid cysts, periorbital cysts account for up to 9–10%. The periorbital dermoid may occur in two variants as per the plane of location: Anterior (superficial) or deep.

Keywords: Choristoma, Medial Dermoid Cyst Congenital, Nasal Dermoid, Proptosis

1. Introduction

Dermoid cysts are a subset of benign heterotopic neoplastic lesions termed as choristomas. They arise from the epidermal rest cells that get pinched during embryogenesis by the underlying developing bony structures. In the pediatric population, the cysts in the periorbital region account for about 10% of head and neck dermoid cysts and generally occur in proximity of frontonasal or frontozygomatic suture. The overall prognosis of these lesions is good but they can rupture and lead to severe inflammation in the surrounding tissues^{1,2}. This report presents a case of an anterior facial medial dermoid cyst in a 7-year-old male child.

2. Case Report

A 7-year-old male child, first in the birth order, was brought with a swelling at the bridge of the nose (Figure 1a-c). The parents had noted a fullness in the area at the age of 9 months and stated that the swelling had progressively enlarged to become clearly noticeable. The patient was born at full term by normal vaginal delivery and had attained all the developmental milestones normally. There was no other significant antenatal or postnatal history. On examination, there was a single,

ovoid, non-tender, smooth, non-pulsatile, mobile, cystic, subcutaneous lump about 2 cm × 1.5 cm located over the right side of root of the nose, inferior to head of right eyebrow, and superior to medial canthus. The lump had minimal surface erythema and absent impulse on coughing. Computed tomography (CT) scan imaging shows a well-defined smooth margin fat-containing extraconal mass located at the right side of root of the nose with no intracranial extension. Bone window revealed a clear indentation of right nasal bone but without any bony erosion and the orbital anatomy was maintained. There were neither perilesional inflammatory changes nor any calcifications.

The clinical presentation and imaging of the lesion were most consistent with a medial dermoid cyst. Excision of the cyst under general anesthesia was planned and informed consent was secured from the parents. The patient underwent an uneventful excision of the cyst through a 2 cm long, transverse skin incision. Histopathological study of the lesion demonstrated a cystic structure lined with stratified squamous keratinizing epithelium with skin adnexal structure elements, consistent with a dermoid cyst. There were no postoperative complications. No recurrence was recorded at 6 years follow-up and the parents were satisfied with the outcome.

*Author for correspondence

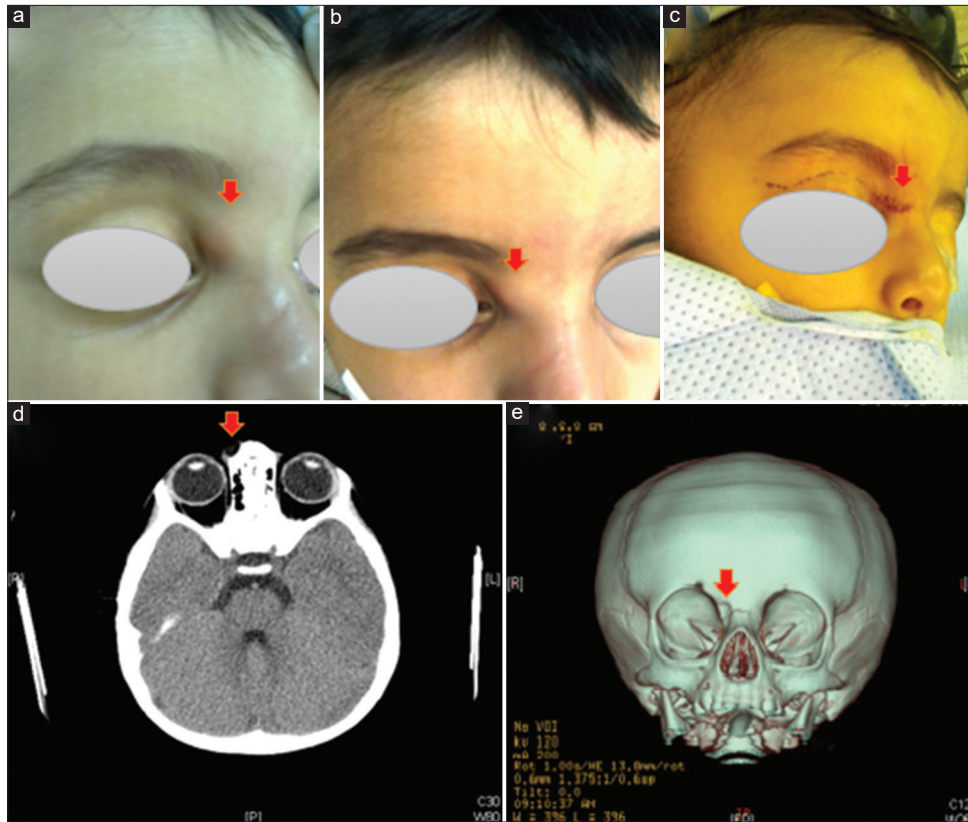


Figure 1. (a) External photograph (lateral view) demonstrates a mass on the right side of root of the nose, under the head of the brow. (b) External photograph (anterior view) demonstrates a mass on right side of root of the nose, under the head of the brow. (c) Immediate post-excision image with a sutured transverse incision. (d) Well-defined smooth margin low attenuating, fat-density extraconal mass located on right side of root of the nose. (e) CT scan (bone window) showing clear indentation of right nasal bone without any erosion.

3. Discussion

Periorbital dermoid cysts are congenital and belong to a subset of benign heterotopic neoplastic lesions termed as choristomas¹. They are common in the pediatric age-group and develop adjacent to the suture lines and progressively enlarge as the child matures.

These lesions are believed to evolve from the dermal and the epidermal rest cells trapped during embryogenesis in the cranial fusion lines as the closure of the neural tube takes place². Histologically, they have a lining of stratified squamous epithelium with dermal adnexa such as hair follicles, sebaceous, and sweat glands. The cyst contents include keratin, hair, smooth muscle, and lipid debris³. Dermoid cysts can be classified into (a) superficial or anterior, and (b) deep varieties⁴.

Superficial dermoids, like the case presented in this report, classically present as painless, firm, somewhat mobile subcutaneous lumps. The lesions are usually

discovered by the parents/guardians in the 1st year of their child's life. With the growth of the child, the periorbital facial fat normally decreases and this factor results in making the cysts more prominent. Rarely the superficial dermoid may rupture due to direct trauma, extruding keratin and thence presenting with acute inflammatory features such as periocular erythema, tenderness, and edema. Deeper orbital dermoids are rare and grow indolently, presenting in the teenage or even late adulthood with the gradual onset of globe dystopia or proptosis and adjacent bony changes or erosion⁵.

Anterior dermoid cysts most commonly occur at the superolateral aspect of the orbit near the frontozygomatic suture and less frequently are encountered as medial lesions at the frontonasal suture as in case presented in this report. Due to the anterior location, these lesions usually do not result in globe displacement, but if proper surgical attention is not sought and the lesion allowed

to grow to a large enough size, they have the significant potential to cause visually significant ptosis.

Imaging studies such as CT or magnetic resonance imaging play an important role in determining the true extent of the facial dermoid cysts and hence in planning their appropriate management. Images should be obtained for all the lesions not located in the superolateral quadrant of the orbit and clinically suspected of being dermoid, due to their tendency to grow stealthily deep into the adjacent structures, creating a dumbbell shape. Imaging is also indicated if the dermoid is nonmobile or presents with features of inflammation or fistulization, and in the presence of proptosis, globe dystopia, temporalis fossa swelling, or optic neuropathy⁶.

The standard of care is complete surgical excision without rupture of the cyst wall. The procedure is usually straightforward for anterior cysts but deep orbital cysts may present a surgical challenge requiring a difficult approach.

4. Conclusion

Periorbital dermoid cysts are congenital choristomas that develop adjacent to the suture lines. Management comprises of imaging studies to determine their extent followed by complete surgical excision.

5. Acknowledgments

The author thanks the parents of the patient for sharing the images and allowing their usage for academic purposes.

6. Authors' Contributions

All the article has been drafted by the author.

7. Financial Support and Sponsorship

None.

8. Conflicts of Interest

None.

9. Ethics Approval and Consent to Participate

Not applicable.

10. Consent for Publication

Yes.

11. References

- Ahuja R, Azar NF. Orbital dermoids in children. *Semin Ophthalmol* 2006;21(3):207-11. <https://doi.org/10.1080/08820530500353963>. PMID: 16912019.
- Yeola M, Joharapurkar SR, Bhole AM, Chawla M, Chopra S, Paliwal A. Orbital floor dermoid: An unusual presentation. *Indian J Ophthalmol* 2009;57(1):51-2. <https://doi.org/10.4103/0301-4738.44486>. PMID: 19075411; PMCID: PMC2661519.
- Reissis D, Pfaff MJ, Patel A, Steinbacher DM. Craniofacial dermoid cysts: Histological analysis and inter-site comparison. *Yale J Biol Med* 2014;87(3):349-57. PMID: 25191150; PMCID: PMC4144289.
- Pham NS, Dublin AB, Strong EB. Dermoid cyst of the orbit and frontal sinus: A case report. *Skull Base* 2010;20(4):275-8. <https://doi.org/10.1055/s-0030-1247631>. PMID: 21311621; PMCID: PMC3023315.
- Pryor SG, Lewis JE, Weaver AL, Orvidas LJ. Pediatric dermoid cysts of the head and neck. *Otolaryngol Head Neck Surg* 2005;132(6):938-42. <https://doi.org/10.1016/j.otohns.2005.03.005>. PMID: 15944568.
- Lin PH, Kitaguchi Y, Mupas-Uy J, Takahashi Y, Kakizaki H. Rescue technique for complete removal of an accidentally ruptured orbital dumbbell deep dermoid cyst: A case report. *Am J Ophthalmol Case Rep* 2018;10:55-58. <https://doi.org/10.1016/j.ajoc.2018.01.044>. PMID: 29780914; PMCID: PMC5956660.