

Case Report

Gigantic adrenal pseudocyst: A case report

Hafiz Zia Farooq Bhatti¹, Farooq Ahmed Rana¹, Ahsan Naseem¹, Zaubaria Shehar Bano¹, Zakauallah Khan¹, Faryal Ufaq¹, Hanzala Khalid¹, Azeem Khalid¹, Shahzaib Maqbool²

¹Department of Surgery, Jinnah Hospital Lahore, ²Graduate of Rawalpindi Medical University, Rawalpindi, Pakistan.

ABSTRACT

Adrenal cystic lesions are uncommon, non-functional, and asymptomatic. Adrenal Pseudocyst is a fibrous cyst devoid of any epithelial or endothelial lining. They have a female predominance with an incidence ratio of 3:1, usually occurring in the 3rd and 4th decade of life. We describe a case of a massive left-sided adrenal pseudocyst in a 50-year-old obese lady who had been experiencing stomach pain and distension for six months before her presentation. Investigations revealed a considerable cyst arising from the left adrenal gland. Excision via midline laparotomy incision was planned. Findings are discussed, including radiology, cytology, histology, and patient management. Adrenal Pseudocyst is a rare lesion, and imaging may mislead in diagnosis. Consider alternative diagnoses including benign and malignant masses of nearby organs, particularly the adrenal, kidney, and pancreas. After surgical excision, a pathological study is necessary for a conclusive diagnosis.

Keywords: Adrenal cyst, Pseudocyst, Excision, Laparotomy, Histology, Hemorrhage

INTRODUCTION

The incidence rate fluctuates between 0.06% and 0.18%.^[1] They are rare, non-functional, and asymptomatic; around 500 cases have been reported in Western literature.^[2] Endothelial (45%), epithelial (9%), parasitic (7%), and pseudocyst (39%) are the four types of adrenal cysts.^[2] The adrenal pseudocyst is a gland-fibrous cyst without any endothelium or epithelial lining. There is a diagnostic dilemma regarding the origin of an enormous adrenal cyst. It usually occurs in the 3rd and 4th decade of life with a female preponderance 3:1.^[3] In our case study, we report a case of a gigantic left-sided adrenal pseudocyst measuring about 25 cm in largest diameter, one of the largest adrenal hemorrhagic pseudocysts.

CASE REPORT

A 50 years old hypertensive and obese woman presented with a 6-months history of abdominal pain and distension. The pain was dull in nature, originating from the left upper abdomen. On examination, a smooth surface mass was palpated in the left-side abdomen with an unreachable lower limit. The mass was dull to percussion and mildly tender to palpation. There was no history of trauma or malignancy.

MANAGEMENT

The biochemical profile showed normal complete blood count (CBC), renal function tests (RFTs) and liver function tests (LFTs). Serum amylase (N:25–125U/L) and lipase (N 0–60 U/L) were 49 and 38 (unremarkable), respectively.

Cancer embryonic antigen (CEA) and Carbohydrate antigen (CA 19-9) levels were normal at 1.53 (N:0–2.5 ng/ml) and 10.9 (N:0–35 U/ml). Hormonal status was also normal; showed serum cortisol 4.8 (N:2.9–17.3 ug/dl), urine metanephrine 90 (<350 ug/day), plasma-free metanephrines 16.98 (N:0–90 pg/ml), urine normetanephrine 117.2 (N:<600 ug/dl), plasma free normetanephrine 20.44 (N:0–190 pg/ml) and urine dopamine level was 60 (N:<600 ug/dl).

Computed Tomography (CT) scan abdomen and pelvis with IV-contrast showed a huge cyst measuring (22 × 22 × 25) involving the left hypochondrium and epigastric region and appears to be arising from the left adrenal gland showing no internal solid component or septations. However, small focal wall calcifications are noted. This cyst displaces the pancreas anterosuperiorly. The left kidney was replaced inferiorly, with its axis rotated laterally [Figure 1].

In a multidisciplinary team (MDT) meeting, the patient was discussed, and a plan for midline excision was formed due to

Corresponding author: Dr. Azeem Khalid, Department of Surgery, Jinnah Hospital Lahore, Pakistan. dr.azeemkhalid@gmail.com

Received: 09 July 2023 **Accepted:** 05 August 2023 **Epub Ahead of Print:** 4 April 2024 **Published:** ** *** **DOI** 10.25259/JHSR_30_2023 **Supplementary available on:** https://doi.org/10.25259/JHSR_30_2023

This is an open-access article distributed under the terms of the Creative Commons Attribution-Non Commercial-Share Alike 4.0 License, which allows others to remix, transform, and build upon the work non-commercially, as long as the author is credited and the new creations are licensed under the identical terms. ©2024 Published by Scientific Scholar on behalf of Journal of Health Science Research

the risk of malignancy associated with the massive size of the cyst. This operation was conducted under general anesthesia with the patient lying supine. A midline laparotomy incision was made, and intraoperative findings revealed a huge cystic mass in the left side of the abdomen from the epigastric area to the pelvic region, which crosses the midline [Figure 2]. The cyst was arising from the left adrenal gland. Around 3 liters of brownish-gray fluid was aspirated from the cyst, and excision of the cyst with complete left-sided adrenalectomy was done. Fluid and cyst were sent for cytology and histopathology, respectively.

Cystic fluid was found negative for malignant cells. Histological examinations of sections revealed adrenal gland parenchyma showing a cystic cavity containing hemorrhagic material and hemosiderin-laden macrophages in the lumen.

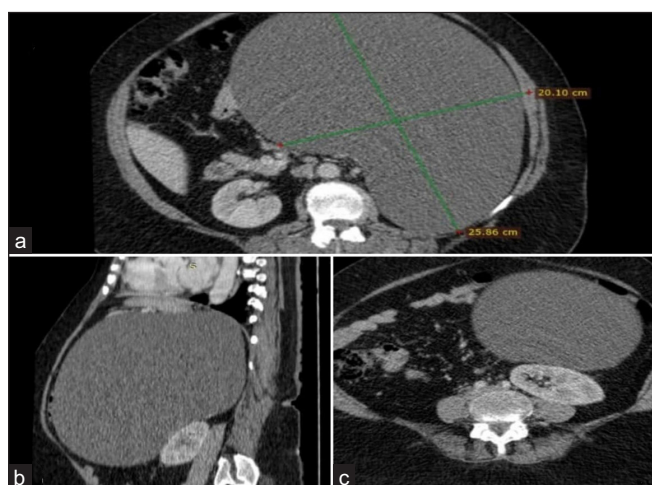

Figure 1: CT-Scan Abdomen with IV-Contrast. Panel (a): Axial view of CT-Abdomen IV contrast showing huge left-sided cyst 25*20 cm with no solid component and septations with few areas of calcifications. Panel (b): Sagittal View of CT-Abdomen IV contrast showing huge cyst arising from left adrenal gland displacing pancreas superiorly and kidneys inferiorly. Panel (c): Axial view of CT-Abdomen showing cyst compressing the left kidney.

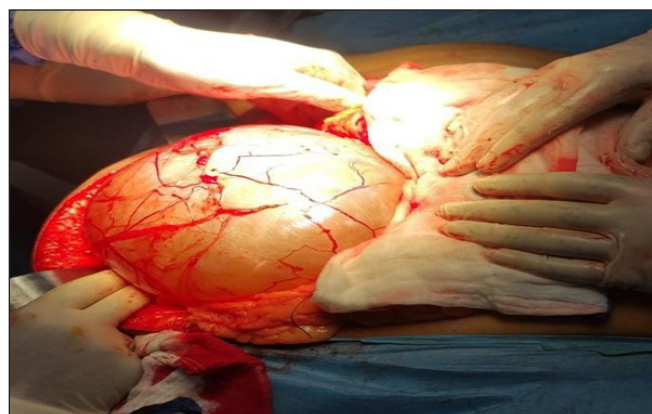


Figure 2: Shiny cyst extending from epigastrium to pelvis and also crossing the midline.

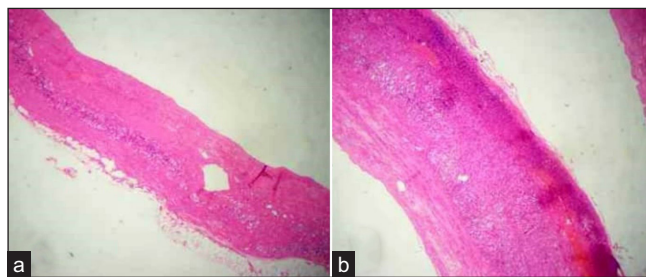


Figure 3: Histopathology: (a) Histological examination of sections reveals adrenal gland parenchyma showing a cystic cavity containing hemorrhagic material and hemosiderin-laden macrophages in the lumen. (b) No definitive cyst lining epithelium is identified in the section examined. No evidence of any granulomatous process of malignancy is seen.

No definitive cyst lining epithelium was identified, and a diagnosis of an adrenal pseudocyst was confirmed [Figure 3].

DISCUSSION

Although benign and may develop at any age, adrenal cysts are more common from the third to the fifth decade of life. In 1966, adrenal cysts classification was modified into four categories: endothelial (45%), pseudocyst (39%), epithelial (9%), and parasitic (7%). Pseudocysts are fibrous-walled cyst that lacks an epithelium. These bleeds are secondary to vascular malformation, trauma, cystic degeneration of the adrenal gland, or vascular neoplasm.^[4] Generally, adrenal cysts are asymptomatic, but larger cysts may present with lumbar pain, vomiting or gastrointestinal discomfort, or a palpable mass. Acute abdomen may occasionally appear, mainly due to rupture, intra cystic bleeding, or infection.^[5] The true origin of adrenal pseudocyst is still controversial. According to one theory, intrarenal hemorrhage is caused by trauma or sepsis. This injury causes a cavity to form with a fibrous, scarred lining that gradually gets bigger over time. Another idea contends that due to swelling and bleeding inside the cyst, adrenal cysts are real cysts that have lost their cellular lining.^[6] Malignant adrenal cysts can be seen in up to 7% of cases, and the risk rises with the pseudocyst size.^[7] Therefore, a careful preoperative workup is mandatory to rule out functioning adrenal carcinoma or pheochromocytoma, especially serum vanillylmandelic acid, serum cortisol, and adrenocorticotropic hormone levels.^[3,7] CT scan is the gold standard for studying adrenal masses with a sensitivity of 85% to 100% and specificity of 95% to 100%.^[8] The appearance of adrenal pseudocyst may range from cystic, solid, or mixed masses on a CT scan. An adrenal pseudocyst with a solid component on a CT scan could be an adrenal tumor. However, no contrast enhancement of solid components on CT confirms a diagnosis of adrenal pseudocyst and helps differentiate it from adrenal carcinoma.^[9] On magnetic resonance imaging (MRI), the cyst has a characteristic homogeneous low T1 or

high T2 signal, with no soft tissue component and internal enhancement.^[8] Voudoukis *et al.* recently demonstrated that endoscopic ultrasound (EUS) is superior to all other imaging modalities for preoperative diagnosis of adrenal cystic lesions, particularly when the pancreatic origin is difficult to rule out by conventional diagnostic methods.^[10] Malignant adrenal tumors, cystic pathologies of the spleen, liver, and kidney, cystic neoplasm of the pancreatic tail, retroperitoneal mucinous cystic neoplasms, and mesenteric and urachal cysts are all included in the differential diagnosis.^[11] Because adrenal pseudocysts are often uncommon lesions, there is disagreement regarding how to treat them. When symptoms are present, a malignancy suspicion exists, and the cyst's size and functioning have increased, surgical excision—either open or laparoscopic—is necessary.^[12] Recent research on laparoscopic adrenalectomy recommends performing the procedure regardless of the size of the adrenal pseudocyst.^[13] They contend that laparoscopic enlarged vision makes it possible to see tiny arteries, nerves, and fascial laminations hidden from view during traditional open surgery.^[14] The laparoscopic approach has several benefits smaller incisions, short hospital stays, and early recovery. The majority of authors, however, choose open adrenalectomy when treating gigantic adrenal pseudocysts because it is challenging to control such sizable masses when there is internal bleeding. Because of the possibility of malignant potential. It is advised to treat cysts larger than 6 cm using open surgery.^[3]

CONCLUSION

The adrenal pseudocyst is a rare lesion. It is usually asymptomatic and diagnosed incidentally on imaging. Symptoms are related to size and local pressure effect. Regarding diagnosis, imaging might be deceiving. In particular, the adrenal, kidney, and pancreas should be considered when diagnosing benign and malignant masses of nearby organs. After surgical excision, a pathological study is necessary for a conclusive diagnosis.

Ethical approval

The research/study complied with the Helsinki Declaration of 1964.

Declaration of patient consent

The authors certify that they have obtained all appropriate patient consent.

Financial support and sponsorship

Nil.

Conflicts of interest

There are no conflicts of interest.

Use of artificial intelligence (AI)-assisted technology for manuscript preparation

The authors confirm that there was no use of artificial intelligence (AI)-assisted technology for assisting in the writing or editing of the manuscript and no images were manipulated using AI.

REFERENCES

1. Carvounis E, Marinis A, Arkadopoulos N, Theodosopoulos T, Smyrniotis V. Vascular adrenal cysts: A brief review of the literature. *Arch Pathol Lab Med* 2006;130:1722–4.
2. Cantisani V, Petramala L, Ricci P, Porfiri A, Marinelli C, Panzironi G, *et al.* A giant hemorrhagic adrenal pseudocyst: Contrast-enhanced examination (CEUS) and computed tomography (CT) features. *Eur Rev Med Pharmacol Sci* 2013;17:2546–50.
3. Stimac G, Katusic J, Sucic M, Ledinsky M, Kruslin B, Trnski D. A giant hemorrhagic adrenal pseudocyst. *Med Princ Pract* 2008;17:419–21.
4. Alaswad F. Adrenal Pseudocyst: Case Report. *Biomed J Sci Tech Res* 2018;10.
5. Azami MA, Lahbali O, El Alami I, Ratbi EA, Zouidia F, Mahassini N. Large Adrenal Pseudocyst: A Case Report. *Surg Sci* 2017;8:197.
6. Vissa S, Rao BS, Rao NM, Grandhi B, Reddy VM. Giant Adrenal Pseudocyst-A Case Report. *Int J Res Rev* 2019;6:83–5.
7. Khoda J, Hertzanu Y, Sebbag G, Lantsberg L, Barky Y. Adrenal cysts: Diagnosis and therapeutic approach. *Int Surg* 1993;78:239–42.
8. Friedrich-Rust M, Schneider G, Bohle RM, Herrmann E, Sarrazin C, Zeuzem S, *et al.* Contrast-enhanced sonography of adrenal masses: Differentiation of adenomas and nonadenomatous lesions. *Am J Roentgenol* 2008;191:1852–60.
9. Wang LJ, Wong YC, Chen CJ, Chu SH. Imaging spectrum of adrenal pseudocysts on CT. *Eur Radio* 2003;13:531–5.
10. Voudoukis E, Velegraki M, Khamaysi I, Karoumpalis I, Kazamias G, Fragaki M, *et al.* Large adrenal cyst masquerading as a pancreatic cystic tumor: A rare diagnosis based on endoscopic ultrasound. *Endosc Int Open* 2018;6:E1109–11.
11. Ates E, Kol A, Gokce GS, Yildiz AE, Erol H. A giant adrenal hemorrhagic pseudocyst mimicking a parapelvic renal cyst: A case report and review of the literature. *Archivio Italiano di Urologia e Andrologia* 2020;92.
12. Kim BS, Joo SH, Choi SI, Song JY. Laparoscopic resection of an adrenal pseudocyst mimicking a retroperitoneal mucinous cystic neoplasm. *World J Gastroenterol: WJG* 2009;15:2923.
13. Ujam AB, Peters CJ, Tadrous PJ, Webster JJ, Steer K, Martinez-Isla A. Adrenal pseudocyst: Diagnosis and laparoscopic management—A case report. *Int J Surg Case Rep* 2011;2:306–8.
14. Yokoyama Y, Tajima Y, Matsuda I, Kamada K, Ikehara T, Uekusa T, *et al.* Differential diagnosis and laparoscopic resection of an adrenal pseudocyst: A case report. *Int J Surg Case Rep* 2020;72:178–82.

How to cite this article: Bhatti HF, Rana FA, Naseem A, Bano ZS, Khan Z, Ufaq F, *et al.* Gigantic adrenal pseudocyst: A case report. *J Health Sci Res.* doi: 10.25259/JHSR_30_2023