

Pyogenic Granuloma of the Oral Cavity: Clinical and Histopathological Features, Etiopathogenesis, and Management

Georges Aoun*

Department of Oral Medicine and Maxillofacial Radiology, Faculty of Dental Medicine, Lebanese University, Beirut, Lebanon
Email: dr.georgesoun@gmail.com

Abstract

Pyogenic granuloma (PG) refers to a non-malignant vascular tumor that usually arises on the skin and mucous membranes. In the oral cavity, the gingiva is the most commonly affected. PG may result from minimal local irritation, chronic trauma, and changes in hormones. It can be found at all ages, especially during the 2nd–5th decades of life. It is more likely to occur in females in whom the hormones estrogen and progesterone are high. This article reviews the clinical and histopathological features of oral PG, as well as its etiopathogenesis, differential diagnosis, and treatment.

Keywords: Inflammatory Hyperplasia, Oral Cavity, Pyogenic Granuloma

1. Introduction

Pyogenic granuloma (PG), also called lobular capillary hemangioma, is a non-malignant vascular tumor that usually affects the skin and mucous membranes, mostly of the oral cavity, and can rarely be found subcutaneously or intravascularly¹. In rare cases, it may arise elsewhere within the gastrointestinal tract. This is an inflammatory hyperplasia resulting from chronic irritants, including trauma, changes in hormones, or certain medications such as oral contraceptives, retinoids, and anticancer drugs²⁻⁴. Oral PG belongs to a group of nodular growths located in the mucosa with histologic features including inflamed fibrous and granulomatous tissue. This group also includes epulis fissuratum, palatal papillary hyperplasia, and pregnancy tumors⁵. The aim of this article is to review the clinical and histopathological features, the etiopathogenesis, the differential diagnosis, and the treatment of oral PG.

2. Clinical Features

Clinically, oral PG may appear as a pedunculated exophytic overgrowth that is extremely soft in consistency. It bleeds easily and has a smooth and shiny overlying mucosa. Oral PG may also manifest as a sessile plaque^{6,7}. The lesion is usually painless, measuring a few millimeters to a few centimeters. It reaches its full size in a few weeks or months⁸. In 75% of the cases, oral PG is located in the gingiva, especially in the interdental space in the maxillary anterior region (Figure 1). It may also affect the lips, the tongue, the buccal mucosa, and the palate⁹.

Oral PG usually presents with no bony involvement. However, in the literature, many cases of bone resorption have been reported¹⁰⁻¹³ (Figure 2).

Oral PG can occur at any age, mainly in the 2nd–5th decades of life¹⁴. It is more likely occurring in females due to the increased levels of hormones such as estrogen and progesterone¹⁵.

*Author for correspondence

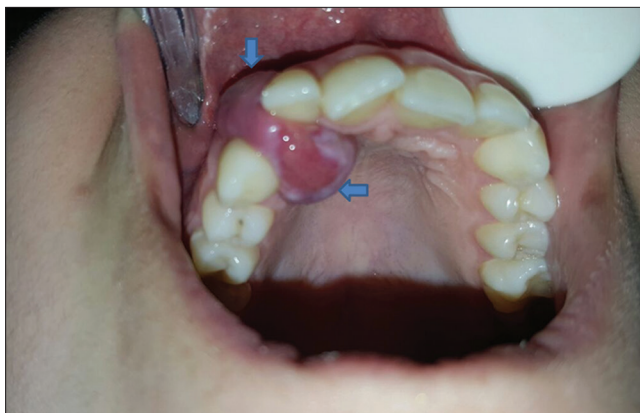


Figure 1. Intraoral photograph showing a gingival pyogenic granuloma.

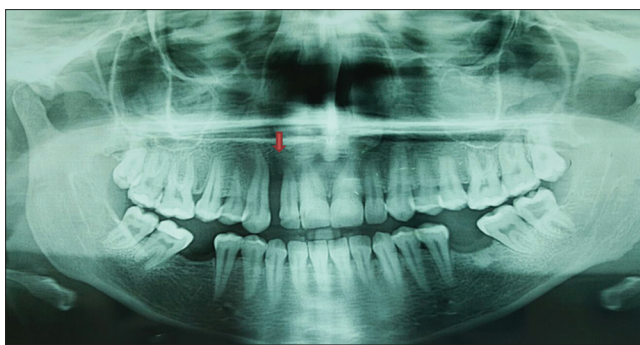


Figure 2. Panoramic radiograph showing the bone resorption between the teeth #12 and #13 caused by the pyogenic granuloma

3. Histopathology

Oral PG typically presents histopathologically as a well-defined lesion composed of vascular sections bordered by normal endothelium. The connective tissue is infiltrated by polymorphic leukocytes. The squamous epithelium is invaginated at the edge of the lesion and ulcerated on the surface. While tumor cells are absent, parakeratosis may be noted¹⁶.

4. Etiopathogenesis

The exact etiology of PG remains unknown^{14,17}. This non-neoplastic inflammatory hyperplasia was once thought to be a bacterial or fungal infection, but it is actually believed to be an inflammatory process reaction associated with exuberant fibrovascular proliferation of the connective tissue^{2,5,14,17}. Various factors are suggested to be implicated in the etiopathogenesis of PG, such

as chronic low-level local irritation from overhanging restorations or calculus, trauma, hormonal changes, bone marrow transplants, reactions to grafts, and certain drugs, including calcium channel antagonists, immunosuppressants, antiseizure drugs, and anticancer medications. Among the latter are “TNF- α antagonists, BRAF inhibitors, tyrosine kinase inhibitors, epidermal growth factor receptor inhibitors, mTOR inhibitors, taxanes, and pyrimidine analogs^{14,18}.”

Oral PG is primarily considered to be connected to pregnancy. According to Kanda and Watanabe¹⁹, “estrogen improves the production of vascular endothelial growth factor in macrophages, leading to the development of PG.” In addition, in their study, Ojanotko-Harri *et al.*²⁰ concluded that “during pregnancy, progesterone may operate as an immunosuppressant in the gingiva, thus preventing an acute inflammatory response against bacteria and resulting in proliferative gingival inflammation.”

5. Differential Diagnosis

Differential diagnosis of PG includes peripheral giant cell granuloma, peripheral ossifying fibroma, Kaposi sarcoma, and metastatic cancer^{2,17}. All these lesions may be clinically identical to PG and must be differentiated based on histopathologic examination.

6. Management

Oral PG is surgically excised to periosteum depth and within 2–3 mm of the clinical limits, followed by curettage of the underlying tissue. The possible causative factors must certainly be removed. During surgery, vigilant monitoring is important because of the vascular nature of the lesion, which leads to abundant bleeding¹⁷. Recurrence after excision has been reported to occur in up to 16% of cases, with gingival PG presenting an elevated recurrence rate^{14,21}. Other surgical techniques that have been used for the treatment of PG include “cryosurgery using liquid nitrogen or a cryoprobe, and laser therapy by means of diode lasers of wavelength 808 to 980 nm, neodymium: yttrium-aluminum-garnet (Nd: YAG), and CO₂ lasers^{7,21-26}.” Sclerotherapy consisting of intralesional injections of ethanol and sodium tetradecyl sulfate was also suggested^{8,27}.

7. Conclusion

PG is a non-neoplastic lesion with an unidentified etiology. In the oral cavity, its diagnosis is challenging, and recurrence after surgical treatment is highly reported. Therefore, their early and accurate diagnosis and treatment, along with regular postoperative follow-ups, are obligatory for best treatment outcome and recurrence prevention.

8. References

- Giblin AV, Clover AJ, Athanassopoulos A, Budny PG. Pyogenic granuloma-the quest for optimum treatment: Audit of treatment of 408 cases. *J Plast Reconstr Aesthet Surg* 2007;60:1030-5.
- Mahabob N, Kumar S, Raja S. Palatal pyogenic granuloma. *J Pharm Bioallied Sci* 2013;5:S179-81.
- Simmons BJ, Chen L, Hu S. Pyogenic granuloma association with isotretinoin treatment for acne. *Australas J Dermatol* 2016;57:e144-5.
- Inoue A, Sawada Y, Nishio D, Nakamura M. Pyogenic granuloma caused by afatinib: Case report and review of the literature. *Australas J Dermatol* 2017;58:61-2.
- Akyol MU, Yalçiner EG, Doğan AI. Pyogenic granuloma (lobular capillary hemangioma) of the tongue. *Int J Pediatr Otorhinolaryngol* 2001;58:239-41.
- Sarwal P, Lapumnuaypol K. Pyogenic granuloma. In: *StatPearls*. Treasure Island, FL: StatPearls Publishing; 2022. Available from: <https://www.ncbi.nlm.nih.gov/books/NBK556077> [Last accessed on 2021 Nov 21].
- Wollina U, Langner D, França K, Gianfaldoni S, Lotti T, Tchernev G. Pyogenic granuloma-a common benign vascular tumor with variable clinical presentation: New findings and treatment options. *Open Access Maced J Med Sci* 2017;5:423-6.
- Jafarzadeh H, Sanatkhani M, Mohtasham N. Oral pyogenic granuloma: A review. *J Oral Sci* 2006;48:167-75.
- Regu P, Aatman S, Murali GV. Pyogenic granuloma of the tongue-a rare clinical finding. *Int J Dent Case Rep* 2013;3:57-61.
- Shenoy SS, Dinkar AD. Pyogenic granuloma associated with bone loss in an eight year old child: A case report. *J Indian Soc Pedod Prev Dent* 2006;24:201-3.
- Lawoyin JO, Arotiba JT, Dosumu OO. Oral pyogenic granuloma: A review of 38 cases from Ibadan, Nigeria. *Br J Oral Maxillofac Surg* 1997;35:185-9.
- Singh VP, Nayak DG, Upoor AS. Pyogenic granuloma associated with bone loss: A case report. *J Nepal Dent Assoc* 2009;10:137-9.
- Martins-Filho PR, Piva MR, Da Silva LC, Reinheimer DM, Santos TS. Aggressive pregnancy tumor (pyogenic granuloma) with extensive alveolar bone loss mimicking a malignant tumor: Case report and review of literature. *Int J Morphol* 2011;29:164-7.
- Kamal R, Dahiya P, Puri A. Oral pyogenic granuloma: Various concepts of etiopathogenesis. *J Oral Maxillofac Pathol* 2012;16:79-82.
- Gomes SR, Shakir QJ, Thaker PV, Tavadia JK. Pyogenic granuloma of the gingiva: A misnomer?-A case report and review of literature. *J Indian Soc Periodontol* 2013;17:514-9.
- McNamara KK, Kalmar JR. Erythematous and vascular oral mucosal lesions: A clinicopathologic review of red entities. *Head Neck Pathol* 2019;13:4-15.
- Thada SR, Pai KM, Agarwal P. A huge oral pyogenic granuloma with extensive alveolar bone loss and “sun-ray” appearance mimicking a malignant tumour. *BMJ Case Rep* 2014;2014:bcr2013202367.
- Iijima Y, Nakayama N, Kashimata L, Yamada M, Kawano R, Hino S, *et al*. A rare case of pyogenic granuloma in the tooth extraction socket. *Case Rep Dent* 2021;2021:5575896.
- Kanda N, Watanabe S. Regulatory roles of sex hormones in cutaneous biology and immunology. *J Dermatol Sci* 2005;38:1-7.
- Ojanotko-Harri AO, Harri MP, Hurttia HM, Sewón LA. Altered tissue metabolism of progesterone in pregnancy gingivitis and granuloma. *J Clin Periodontol* 1991;18:262-6.
- Chawla K, Lamba AK, Faraz F, Chawla K. Treatment of pyogenic granuloma using Er, Cr: YSGG laser. *Int J Laser Dent* 2013;3:29-32.
- Rizwanulla T, Koirala B, Sharma S, Adhikari L, Pradhan A. Pyogenic granuloma: A case report. *Health Renaiss* 2010;8:196-8.
- Parajuli R, Maharjan S. Unusual presentation of oral pyogenic granulomas: A review of two cases. *Clin Case Rep* 2018;6:690-3.
- Al-Mohaya MA, Al-Malik AM. Excision of oral pyogenic granuloma in a diabetic patient with 940nm diode laser. *Saudi Med J* 2016;37:1395-400.
- Erbarar GN, Senguven B, Gultekin SE, Cetiner S. Management of a recurrent pyogenic granuloma of the hard palate with diode laser: A case report. *J Lasers Med Sci* 2016;7:56-61.
- Truschneegg A, Acham S, Kqiku L, Beham A, Jakse N. CO₂ laser excision of a pyogenic granuloma associated with dental implants: A case report and review of the literature. *Photomed Laser Surg* 2016;34:425-31.
- Arunmozhi U, Priya RS, Kadhiresan R, Sujatha G, Shamsudeen-SS SM. A large pregnancy tumor of tongue-a case report. *J Clin Diagn Res* 2016;10:ZD10-2.